

## Letter to the Editor

Case report should be written in the form of **Letters to the Editor** which present preliminary reports of unusual urgency, significance and interest. Letters to the Editor do not contain an abstract, and apart from keywords there is no obligation to divide the text into sections. In all other respects, the directions for full papers should be followed.

# Sample

## Letter to the Editor

---

### Angiofibrolipoma of the spermatic cord

Qing-Li Liu<sup>1</sup>, Bao Tian<sup>1</sup>, Hui Zhang<sup>2</sup> and De-Shan Qiao<sup>1</sup>

<sup>1</sup>Department of Urology, The First Hospital of Qinhuangdao, Qinhuangdao 066000, China

<sup>2</sup>Department of Pathology, The First Hospital of Qinhuangdao, Qinhuangdao 066000, China

Correspondence: Dr Qing-Li Liu, Department of Urology, The First Hospital of Qinhuangdao, Qinhuangdao 066000, China. E-mail: [liuqingli@hotmail.com](mailto:liuqingli@hotmail.com)

Dear Sir,

I am Dr Qing-Li Liu, from the Department of Urology of the First Hospital of Qinhuangdao in Qinhuangdao, Hebei Province, China. I write to present a case report of spermatic cord angiofibrolipoma.

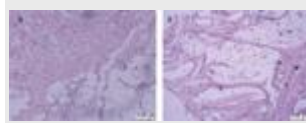
Angiofibrolipoma is a histological variant of lipoma, which usually presents as a solitary, subcutaneous, circumscribed lesion in the back, neck or shoulders. Here, we report a case of angiofibrolipoma of the spermatic cord. To our knowledge, such a case has not been previously reported in the literature.

A 3-year-old boy presented with a right inguinal mass that had first been noticed 1 month earlier. On physical examination, the mass was located in the right spermatic cord and felt elastic, with no tenderness. The transillumination test was negative. Ultrasonography of the spermatic cord revealed a cystic-solid echo mass lesion, 2.5 cm in diameter, with minimum blood flow.

Under general anaesthesia, a 3-cm inguinal oblique incision was made and the spermatic cord was isolated and occluded with a noncrushing clamp at the level of the internal ring. A tumour was found under the internal spermatic fascia; the tumour had a well-circumscribed boundary and was not adjacent to the right testicle

and epididymis. The spermatic vessels and vas deferens were identified posterior to the mass. A 0.2-cm-thick pseudo-capsule surrounded the entire tumour. After the spermatic vessels and vas deferens were securely protected, the tumour was completely removed. Macroscopic examination revealed that the cut surface of the tumour was a multilocular cyst filled with blood, and there were no necrotic or cystic changes. The pathological examination revealed mature adipocytes, blood vessels and dense collagenous tissue ([Figure 1](#)), without the evidence of mitosis or cellular pleomorphism. These findings were consistent with angiofibrolipoma. At 6-month follow-up, there was no evidence of recurrence and the right testicle size was normal.

**Figure 1.**



A histological study (H&E stain) showed the three characteristic findings of angiofibrolipomas: mature adipocytes, blood vessels and dense collagenous tissue. (A): Low-power and (B): high-power views. Scale bar = 125  $\mu$ m

[Full figure and legend \(220K\)](#)

Tumours of the spermatic cord are rare. Overall, 30% of such tumours are malignant; and the rest are benign. Lipoma is the most common benign lesion; among the others are leiomyomas, dermoid cysts, epidermoid cysts and lymphangiomas <sup>[1]</sup>. The conventional lipoma is a collection of mature adipocytes arising from subcutaneous tissues of the trunk, neck and proximal extremities <sup>[2]</sup>. Histological variants of lipomas include fibrolipomas, angiolipomas, angiofibrolipomas, angiomyolipomas and infiltrating angiolipomas. These lesions are categorized according to their content of fat, muscle, blood vessel and connective tissue. The growths are not encapsulated but are histologically distinct from surrounding tissues. They have low-to-moderate cellularity and are not clinically aggressive <sup>[3, 4]</sup>.

Angiofibrolipomas are a mixture of mature adipocytes, vascular tissue and collagenous connective tissue. To our knowledge, the present case study is the first report of a spermatic cord angiofibrolipoma. The patient presented with an elastic inguinal mass on physical examination, and the diagnosis required histopathological assessment. Perhaps a preoperative incisional biopsy of the lesion could have confirmed the diagnosis before definitive resection. However, as with any lipoma, complete surgical excision and histopathological confirmation of margins are adequate for both diagnosis and treatment. During the operation, we found a fibrous pseudo-capsule, which was formed through a desmoplastic reaction <sup>[5]</sup>. The

pseudo-capsule was helpful in the tumour resection and in protecting the spermatic vessels and vas deferens from damage. In such cases, surgical excision, histological examination and long-term follow-up for recurrence are recommended.

### **Conflict of interest**

There is no conflict of interest.

### **References**

1. Ozgur A, Tarcan T, Simsek F, Ahiskali R. An unusual tumor of the spermatic cord: myositis ossificans. *Arch Esp Urol* 2003; **56**: 1072–4.
2. Jacob A, Kneile J, Welling DB. Angiofibrolipoma of the ear canal. *Laryngoscope* 2005; **115**: 1461–2.
3. Kershisnik W, McCarthy DJ, O'Donnell E. Angiofibrolipoma. A histologic variant of the lipoma. *J Am Podiatr Med Assoc* 1986; **76**: 67–70.
4. Liggett AD, Frazier KS, Styer EL. Angiolipomatous tumors in dogs and a cat. *Vet Pathol* 2002; **39**: 286–9.
5. Gómez-Román JJ, Val-Bernal JF, Fernández F. Mucinous cystadenocarcinoma of the vermiform appendix presenting as a renal tumor. *J Urol* 1995; **154**: 1122–4.